

Ospedale 'S. CAMILLO'
Ospedale Classificato ed Equiparato
Via Giovanelli, 19 - 38100 TRENTO
Tel. 0461-216111 - Fax 0461-230334

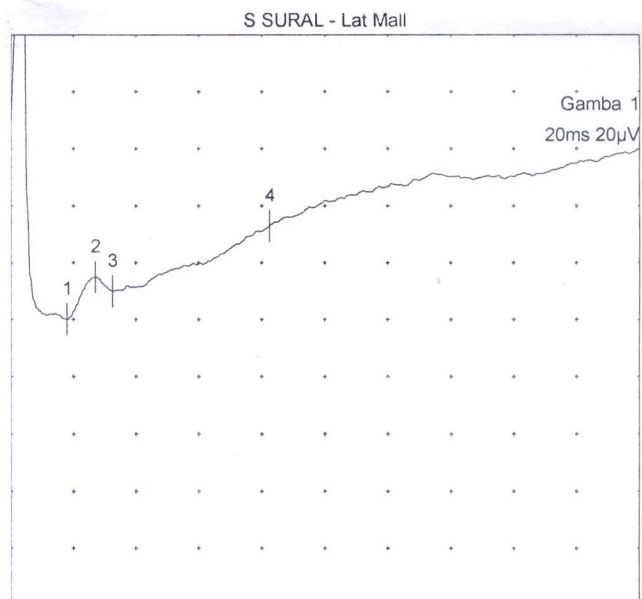
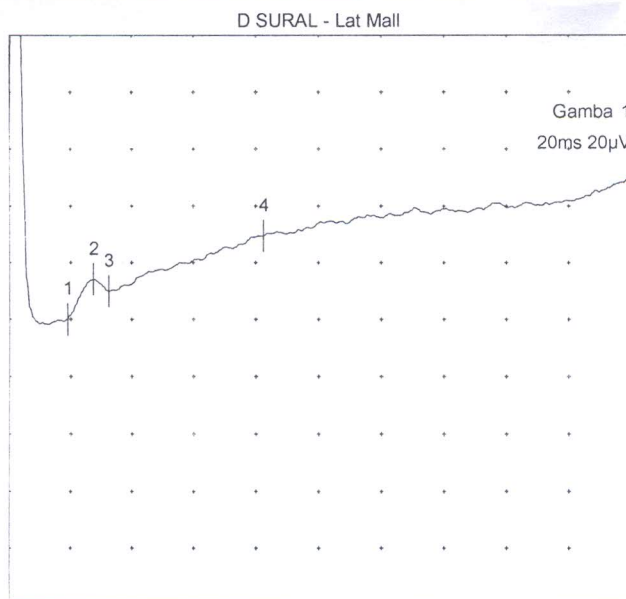
ESAME ELETTROMIOGRAFICO

Pazienti: ENIO ANTONIO SOLINO
Indirizzo: TRENTO
Data di nascita: 24/11/1947
Ultima visita: 71 Anni 10 Mesi

Quesito clinico: stenosi vertebrale: radicolopatia?

Sensory NCS

Nervo / Posizioni	Pos. reg	Lat. ms	Amp.1-2 μ V	Dist. cm	Vel. m/s
D SURAL - Lat Mall					
Gamba	Mall.Lat	1,90	14,1	9	47,4
S SURAL - Lat Mall					
Gamba	Mall.Lat	1,80	14,9	9	50,0



Motor NCS

Nervo / Posizioni	Lat.dist. ms	Ampezza mV	Distanza cm	Velocità m/s
S COMM PERONEAL - EDB				
Caviglia	3,10	1,5		
T.Fibula	10,65	1,2	34	45,0
D COMM PERONEAL - EDB				
Caviglia	2,95	7,0		
T.Fibula	10,55	6,0	32	42,1

EMG Summary Table	Spontaneous					MUAP			Recruitment
	IA	Fib	PSW	Fasc	H.F.	Amp	Dur.	PPP	Pattern
S. TIB ANTERIOR	N	None	++	None	None	A	A	A	IR
D. TIB ANTERIOR	N	None	None	None	None	A	A	A	IR
D. GASTROCN (MED)	N	None	None	None	None	N	N	N	N
S. GASTROCN (MED)	N	None	None	None	None	N	N	N	N
S. VAST MEDIALIS	N	None	None	None	None	N	N	N	N
D. VAST MEDIALIS	N	None	None	None	None	N	N	N	N

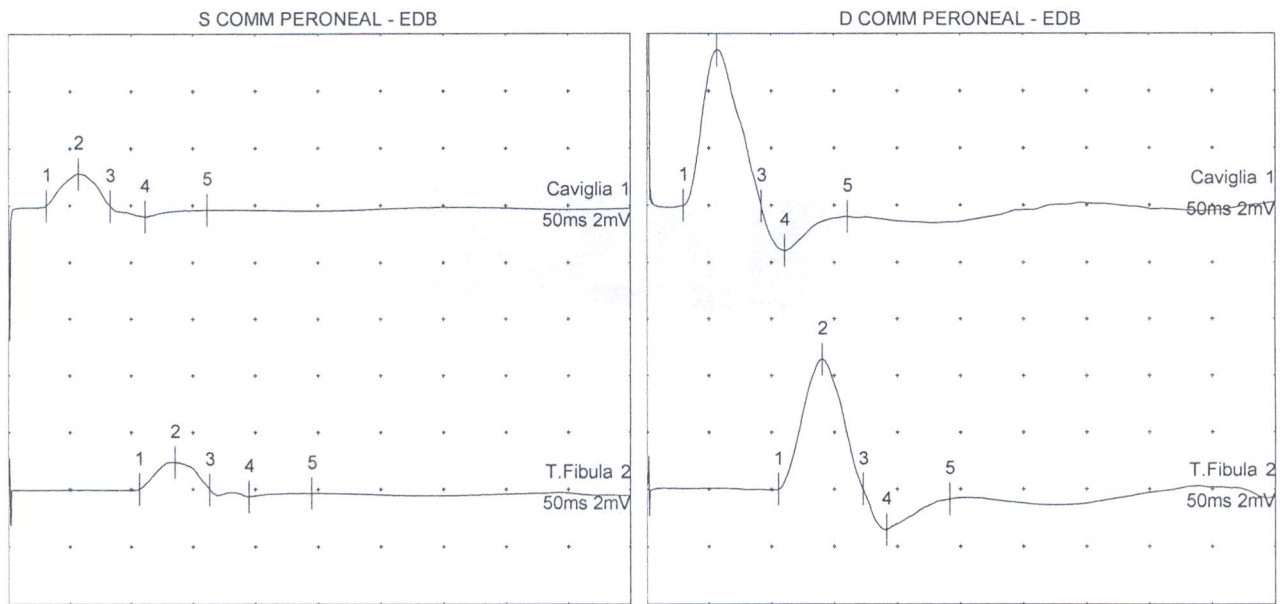
Conclusioni

SI RILEVANO SEGNI DI SOFFERENZA NEUROMUSCOLARE NEI DISTRETTI DI L5 BILATERALE: DI GRADO MEDIO A SINISTRA OVE E' PRESENTE ATTIVITA' SPONTANEA , DI GRADO LIEVE A DESTRA.

CONDUZIONE NERVOSA PERIFERICA NELLA NORMA

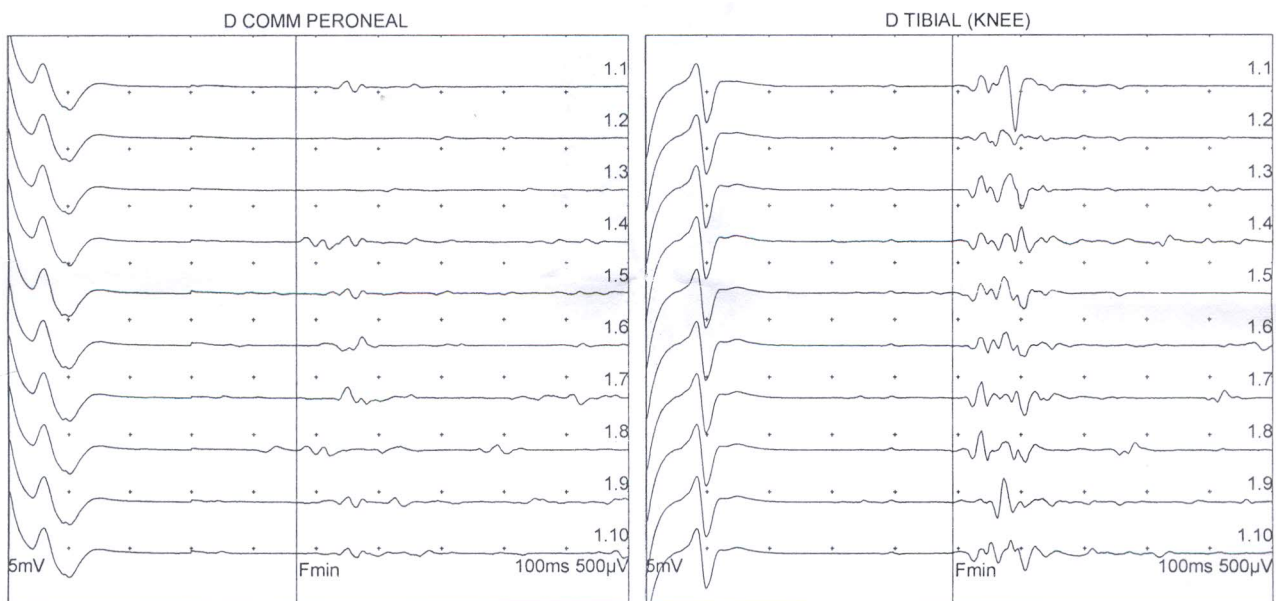
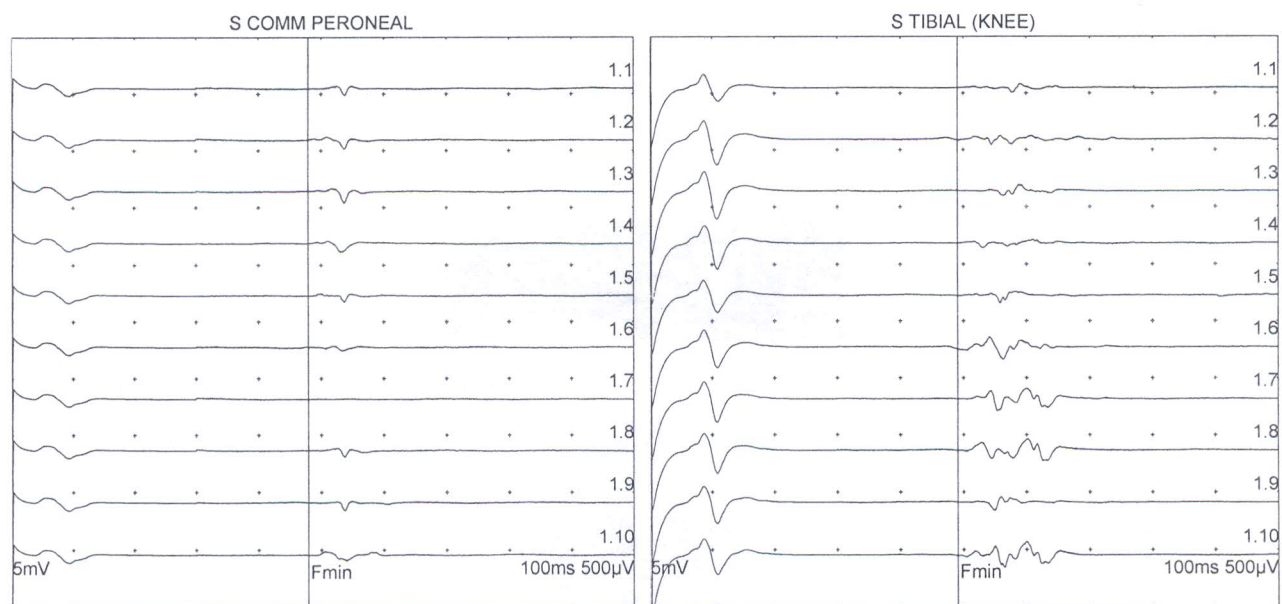
Dr. G.P. Zanette



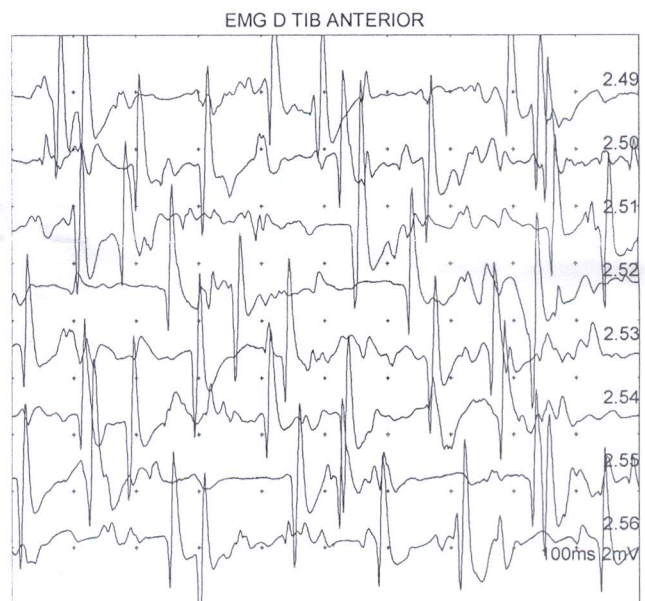
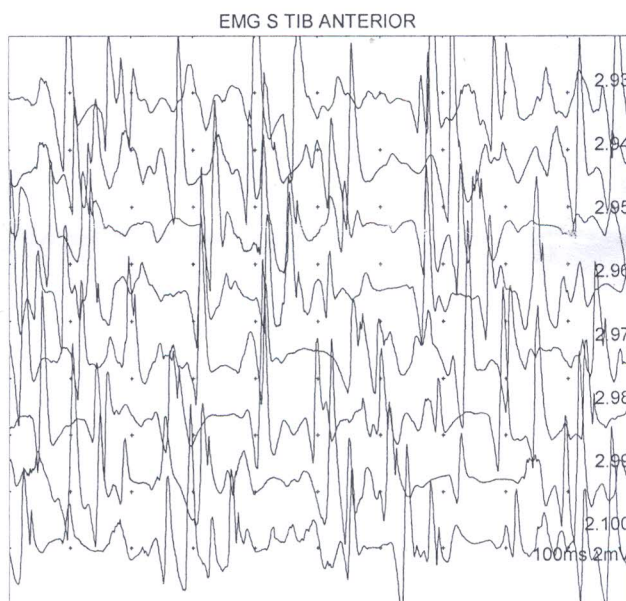
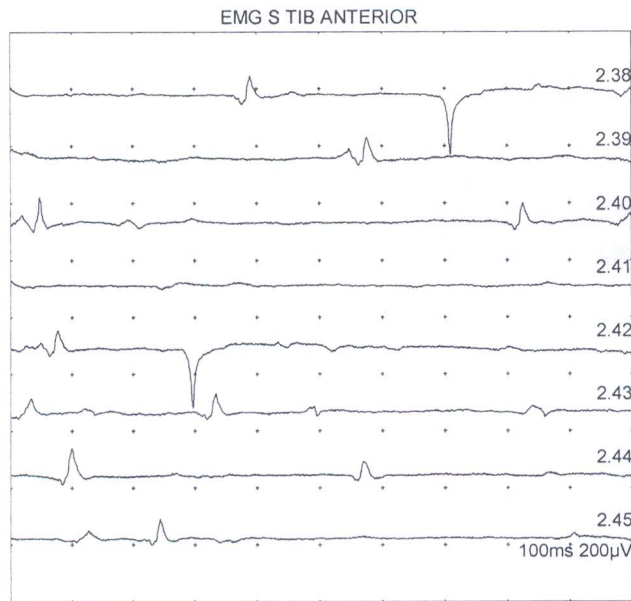


F Wave

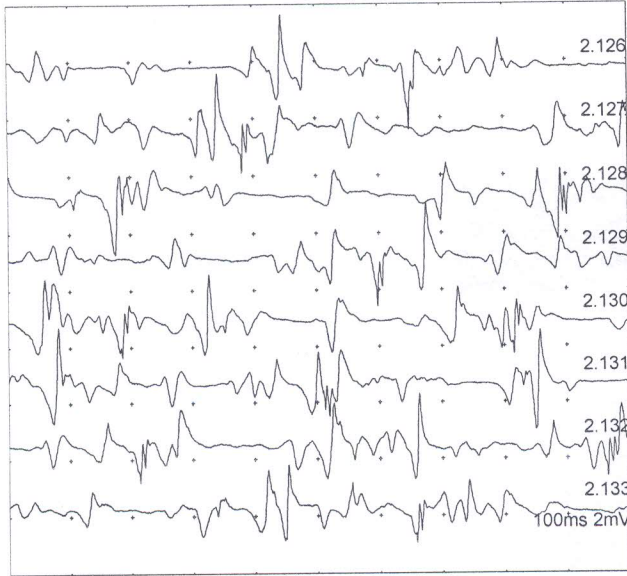
Nervo	Fmin ms
S COMM PERONEAL	47,95
S TIBIAL (KNEE)	49,10
D COMM PERONEAL	46,90
D TIBIAL (KNEE)	49,15



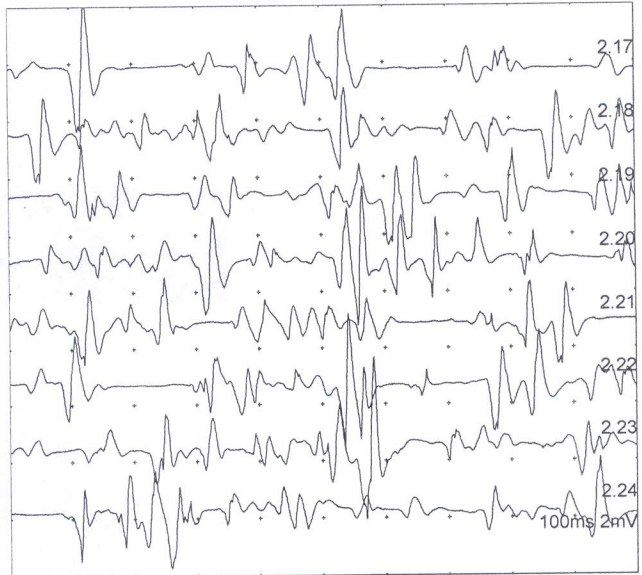
EMG



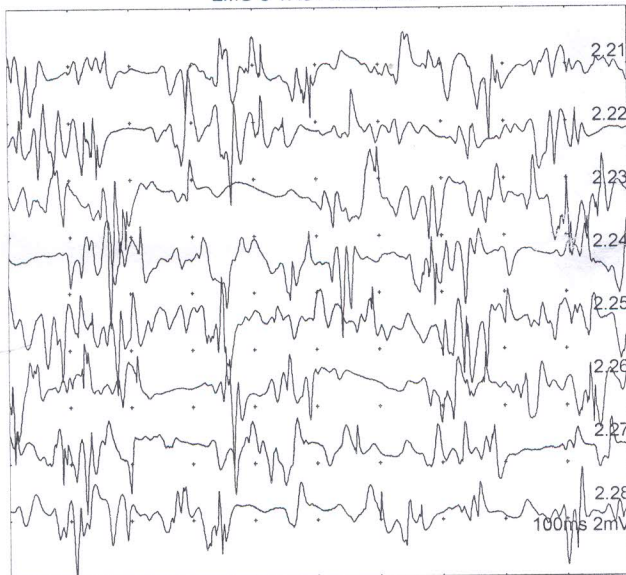
EMG D GASTROCN (MED)



EMG S GASTROCN (MED)



EMG S VAST MEDIALIS



EMG D VAST MEDIALIS

